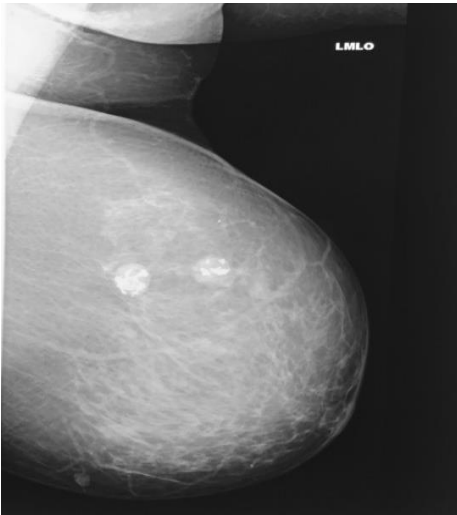
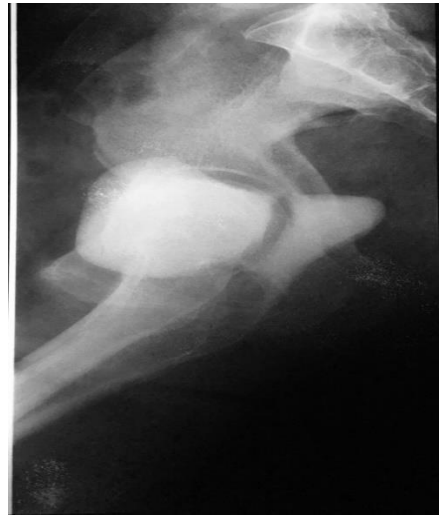
**RADIOLOGY SECTION  
Women (CT IMAGES)**

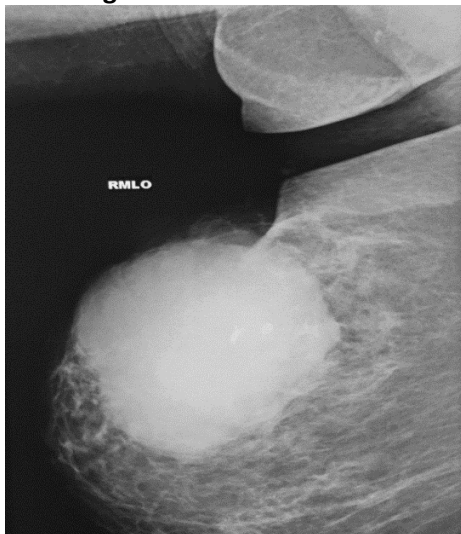
**Manal Niazi  
Associate Professor Department of Radiology  
Islamabad Medical and Dental College**



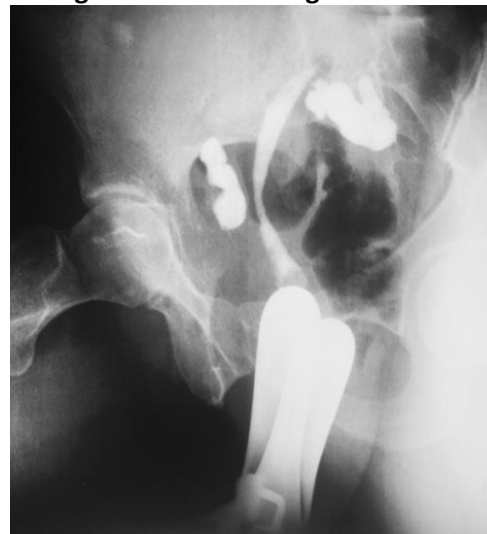**Fig 1: Mammogram-Small Calcified Fibroadenoma**



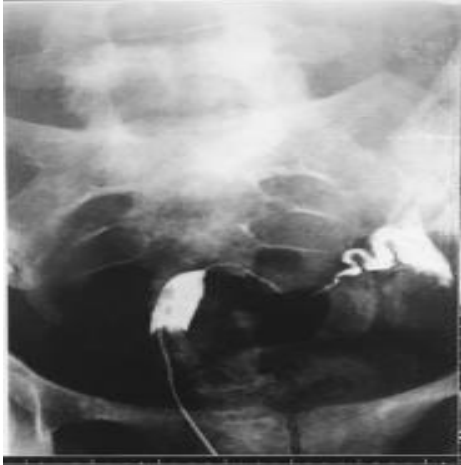**Fig 2: HSG - Vesicovaginal Fistula**



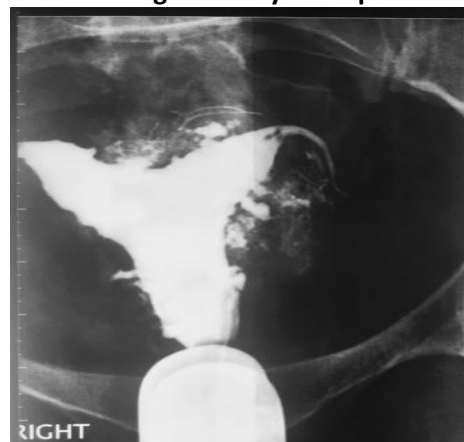**Fig 3: Mammogram-Large Fibroadenoma**



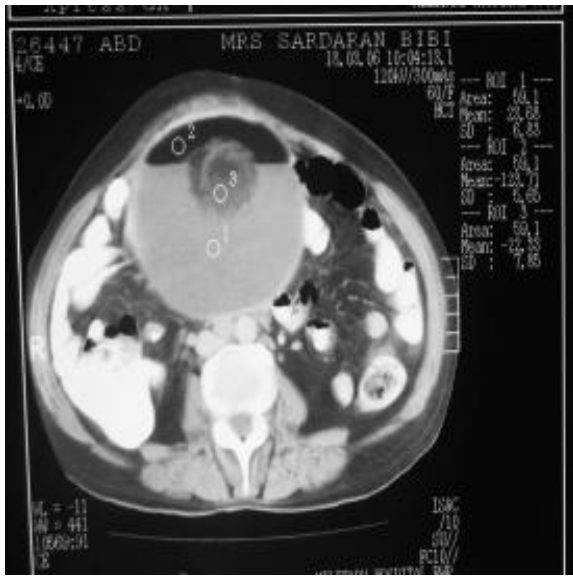**Fig 4: HSG-Uterine Fibroid And B/L Tubal Blockage with Hydrosalpinx**



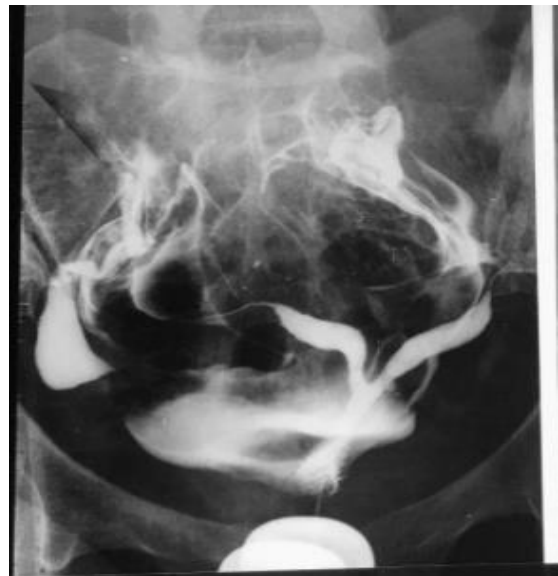**Fig 5: HSG - Unicornuate Uterus**



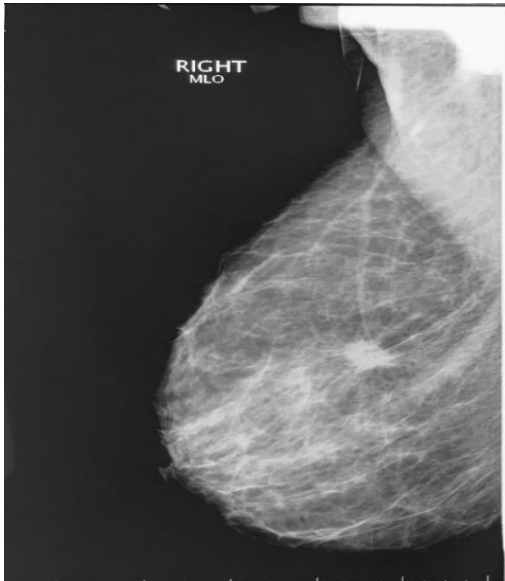
**Fig 6: HSG - Adenomyosis with B/L Tubal Blockage**



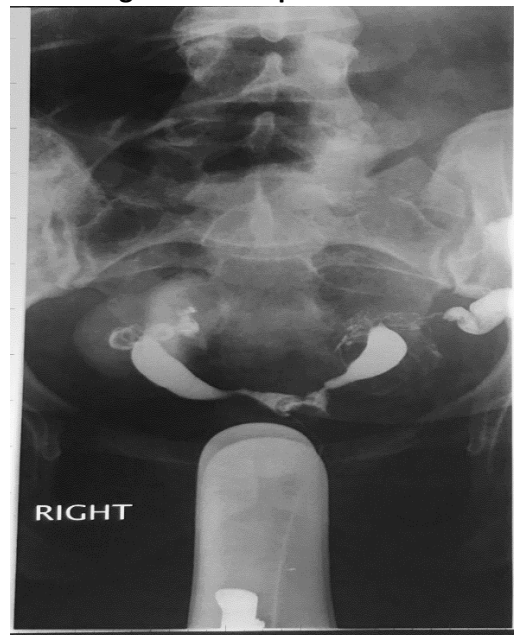**Fig 7: CT - Dermoid Cyst with Malignant Transformation**



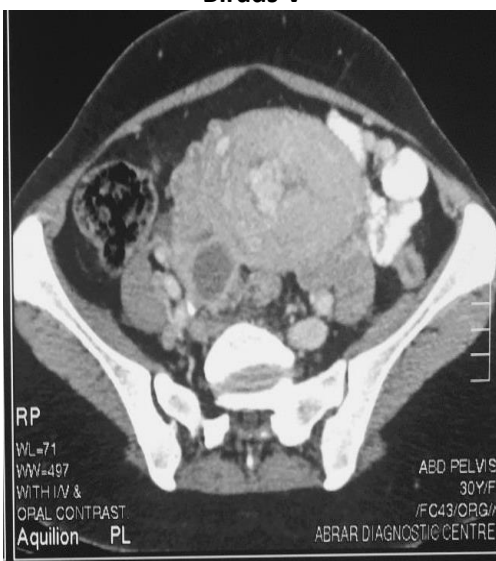**Fig 8: HSG - Septate Uterus**



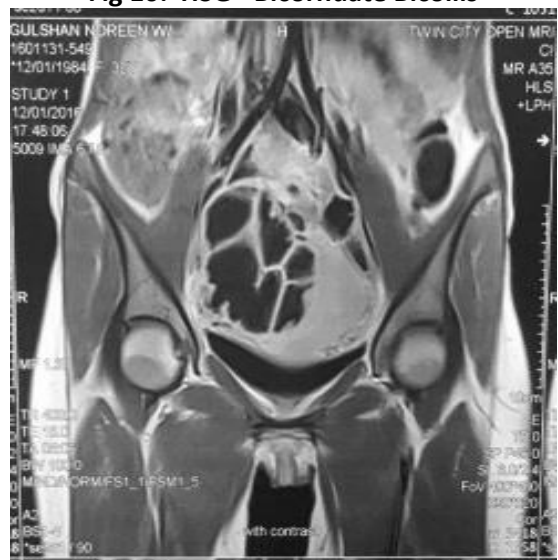**Fig 9: Mammogram - Spiculated Mass Birads V**



**Fig 10: HSG - Bicornuate Bicollis**



**Fig 11: CT - Hydatiform Mole**



**Fig 12: MRI - Inflammatory Tubo Ovarian Mass**